

The Severe Flexible Flatfoot: A Combined Reconstructive Procedure with Rerouting of the Tibialis Anterior Tendon

Hazem Mossad El-Tayeby, Dr Ch Orth

A combined procedure is described that addresses all the components at fault in the severely flexible flatfoot deformity in children. The Evans calcaneal distraction wedge osteotomy will lengthen the lateral column, correcting the heel valgus and forefoot abduction. A naviculo-first cuneiform wedge resection (medial and plantar) and fusion will shorten and reshape the collapsed medial arch. This is augmented by reconstruction and plication of the lengthened plantar ligaments, with plantar rerouting of the tibialis anterior tendon to act as a strong plantar ligament. In addition, shifting the tibialis anterior's pull proximally acts as a sling to the talar head. Z plasty of the tight tendo Achillis is always needed. Nineteen feet in 11 patients were the subject of this study. The period of follow-up ranged from 8 to 42 months. The results were assessed according to the relief of foot strain and calf pains, improvement in footwear, general activity, and foot shape. To evaluate foot shape, reconstruction of the medial arch and heel posture were assessed. The children and parents were satisfied with the final results in 17 feet (89.5%). Improvement of the radiological measurements was evident and was statistically significant. (The Journal of Foot & Ankle Surgery 38(1):41-49, 1999)

Key words: arthodesis, El-Tayeby procedure, flatfoot, foot disorders, pediatric, pes planus

The clinical appearance of the severe flexible flatfoot consists of a collapsed medial longitudinal arch, heel valgus, forefoot abduction, heel cord tightness, and forefoot supinatus or varus (1). On reviewing the literature, surgical treatment has been reserved for children with symptomatic severe flexible flatfoot, not responding to the usual conservative measures (2-6). Surgical procedures fall into three general categories: 1) tendon transfer or lengthening, 2) osteotomy, and 3) arthodesis (5). However, no surgical technique is universally accepted. In this study, a combined reconstructive technique is described that addresses all components of the deformity in one sitting.

Materials and Methods

Nineteen feet in 11 patients (four males and seven females) were the subject of this study performed in the Insurance Hospital for School Children in Alexandria. The ages ranged from 9 to 14 years (average, 10.7 years). The follow-up period was from 8 to 42 months (average, 29 months). Most of the patients presented with their

parents in the outpatient clinic asking for referral to the physiotherapy department for the periodical dispensing of medical shoes or shoe inserts for flatfeet. Eleven parents agreed for their children to have surgery to address one or more of the following complaints: foot strain on long standing (10 patients), excessive footwear (eight patients), unsightly appearance (11 patients), and generalized inactivity with poor participation in physical activity that requires running or jumping (five patients). Two patients had previous surgery. One had a unilateral overcorrection of a congenital talipes equino-varus when she was 1 year old. The other had a failed overcorrection for severe flexible flatfoot in both feet using the Evans procedure alone 2 years earlier.

Radiologic Assessment

The radiological assessment of the result was based on four angles. Three were taken in the weightbearing lateral view, namely the talo-first metatarsal angle (TIMT), the lateral talo-horizontal angle (T-H), and the calcaneal pitch angle (CP) (Fig. 1). According to Mosca (5), the normal values of these angles are as follows: the TIMT normal average value is 5° (2 SD; range, -7° to 20°), the T-H normal average value is 27° (2 SD; range, 15°-37°), the CP normal average value is 25° (2 SD; range, 15°-30°). The fourth angle was measured on a weightbearing anteroposterior view, namely the talo-first metatarsal angle, which reveals the degree of talonavicular

From the Department of Orthopaedic Surgery, Faculty of Medicine, Menoufia University, Egypt. Address correspondence to: Hazem El-Tayeby, Dr Ch Orth, 7 Ahmed Fathy St., Gleem, Alexandria, Egypt.

Received for publication January 1998; accepted in revised form for publication October 1998.

The Journal of Foot & Ankle Surgery 1067-2516/99/3801-0041\$4.00/0 Copyright © 1999 by the American College of Foot and Ankle Surgeons




FIGURE 1 The radiological measurements in a flatfoot. *a*, In the weightbearing lateral view: angle A, the calcaneal pitch (CP) angle is reduced; angle B, the talo-horizontal (T-H) angle is increased; and angle C, the talo-first metatarsal (T1MT) angle is increased. *b*, In the weightbearing anteroposterior view the talo-first metatarsal angle is negative (the first metatarsal is deviated laterally relative to the talus).

subluxation. Normally the axis of the talus coincides with that of the first metatarsal.

Principles of Surgical Treatment

1. For heel valgus and forefoot abduction, the Evans calcaneal osteotomy allowed lengthening of the lateral column and shifting of the laterally subluxed navicular medially over the talar head (Fig. 2).
2. For the collapsed medial longitudinal arch and forefoot supinatus, arthrodesis of the naviculo-cuneiform joint with appropriate wedge resection-based plantar and medial (Fig. 2), reconstruction and shortening of the lengthened plantar ligament (talonavicular joint capsule, spring ligament, and tibialis posterior tendon insertion (Fig. 3), and plantar rerouting of the tibialis anterior tendon to act as a strong plantar support were performed (Fig. 4).
3. Z plasty was performed to lengthen tight tendo Achillis.

Surgical Procedure

A longitudinal incision is made over the calcaneocuboid joint which should be identified to avoid injury to its capsule (Fig. 5). Dorsal subluxation of the distal calcaneal fragment may occur during distraction of the osteotomy site if the calcaneocuboid joint capsule is disrupted. A longitudinal osteotomy is made over the lateral aspect of the calcaneus 1.0–1.5 cm proximal to the calcaneocuboid joint. An osteotome is used as a spreader, and a trapezoid-shaped cancellous iliac bone graft 1.0–1.5 cm in thickness is harvested, fenestrated, and impacted in

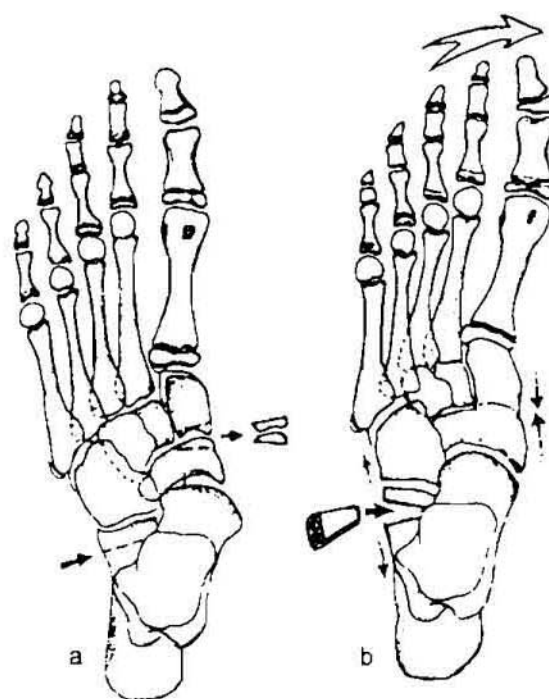


FIGURE 2 The osseous reconstruction procedures: *a* and *b* show the site of the lengthening calcaneal distraction osteotomy laterally. Medially naviculo-first cuneiform wedge resection will allow reconstruction of the medial arch, besides relieving compressive forces on the iliac graft laterally.

the opened wedge (Fig. 5b). Although the graft is usually stable, one or two K-wires are used to transfix it, thereby ensuring its stability. Inspection of the foot at this stage will reveal that the forefoot has become adducted, the heel

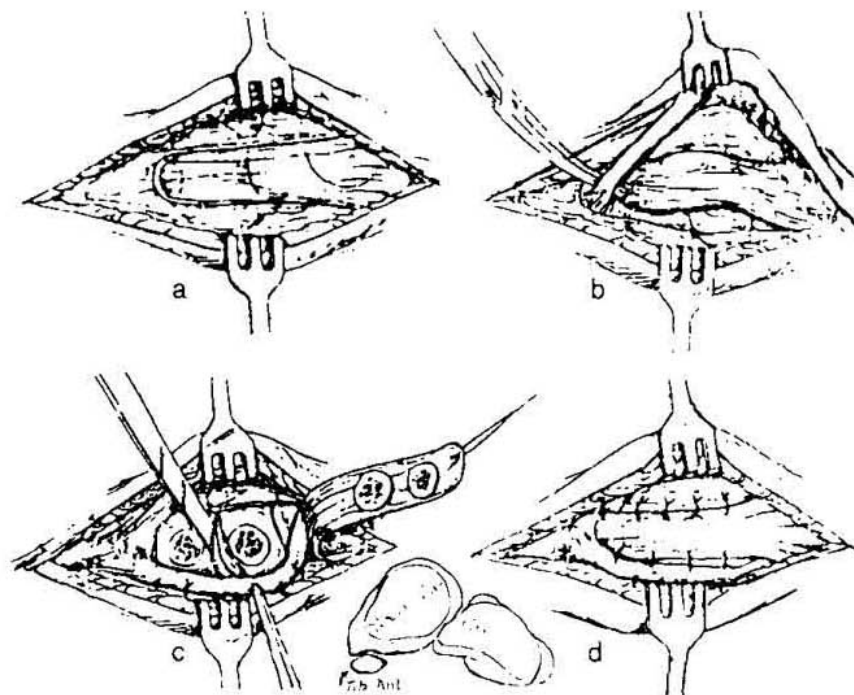


FIGURE 3 The medial soft-tissue reconstruction procedures: *a* shows medial incision and the outline of the osteoperiosteal flap fashioned from the medial plantar ligamentous complex. *b*, the tibialis anterior is identified and mobilized 10–15 cm proximally, keeping its insertion undisturbed. The osteoperiosteal flap is freed. *c*, the osteoperiosteal flap is reflected, the tibialis anterior tendon is pulled down to traverse the plantar aspect of the naviculo–cuneiform and talonavicular joints, kept their in a shallow groove prepared on the plantar aspect of the navicular tuberosity and sutured to the surrounding soft tissues. Note wedge resection from the naviculo–first cuneiform joint-based medial and plantar will allow reformation of the medial arch. *d*, The osteoperiosteal flap is turned to cover the tibialis anterior tendon, plicated, and sutured to the surrounding soft tissues and underlying tendon.

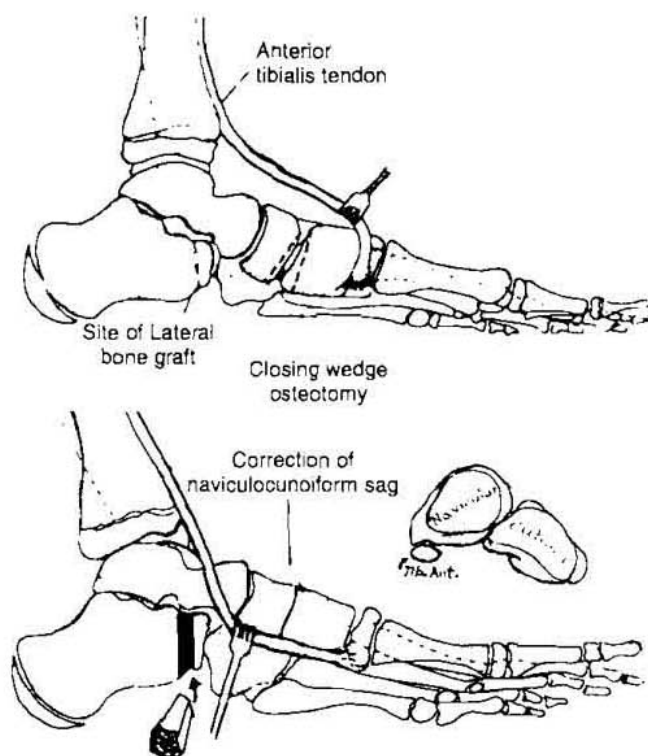


FIGURE 4 Rerouting of the tibialis anterior tendon.

has moved into varus, and dorsiflexion of the ankle has become less free, unmasking the tight tendo Achillis.

Lengthening of the tendo Achillis is done through a posteromedial incision to allow 10°–15° of dorsiflexion. Plication of the medial plantar structures and naviculo–first cuneiform fusion is done through another transverse incision starting from the base of the first metatarsal to the medial malleolus. An osteoperiosteal flap (1.5 cm wide and 5.0 cm long) is fashioned from the plantar ligaments of the talonavicular and naviculo–cuneiform joints including the insertion of the tibialis posterior into the navicular. This is reflected proximally. The naviculo–first cuneiform joint is then identified and a wedge-based plantar and medial is resected. Two crossing K-wires are mandatory to approximate the raw surfaces together. Plantarflexion and pronation of the forefoot is evident with restoration of the medial arch (Fig. 5c). Now keeping its insertion undisturbed, the tibialis anterior tendon is mobilized proximally for 10–15 cm, and while putting the ankle in 10°–15° of dorsiflexion, the distal end of the tendon is pulled down to traverse the plantar aspect of the naviculo–first cuneiform fusion and talonavicular joint (Fig. 5c). Now a gutter is fashioned under the navicular tuberosity to accept and maintain the tibialis anterior in position. The tibialis anterior tendon is

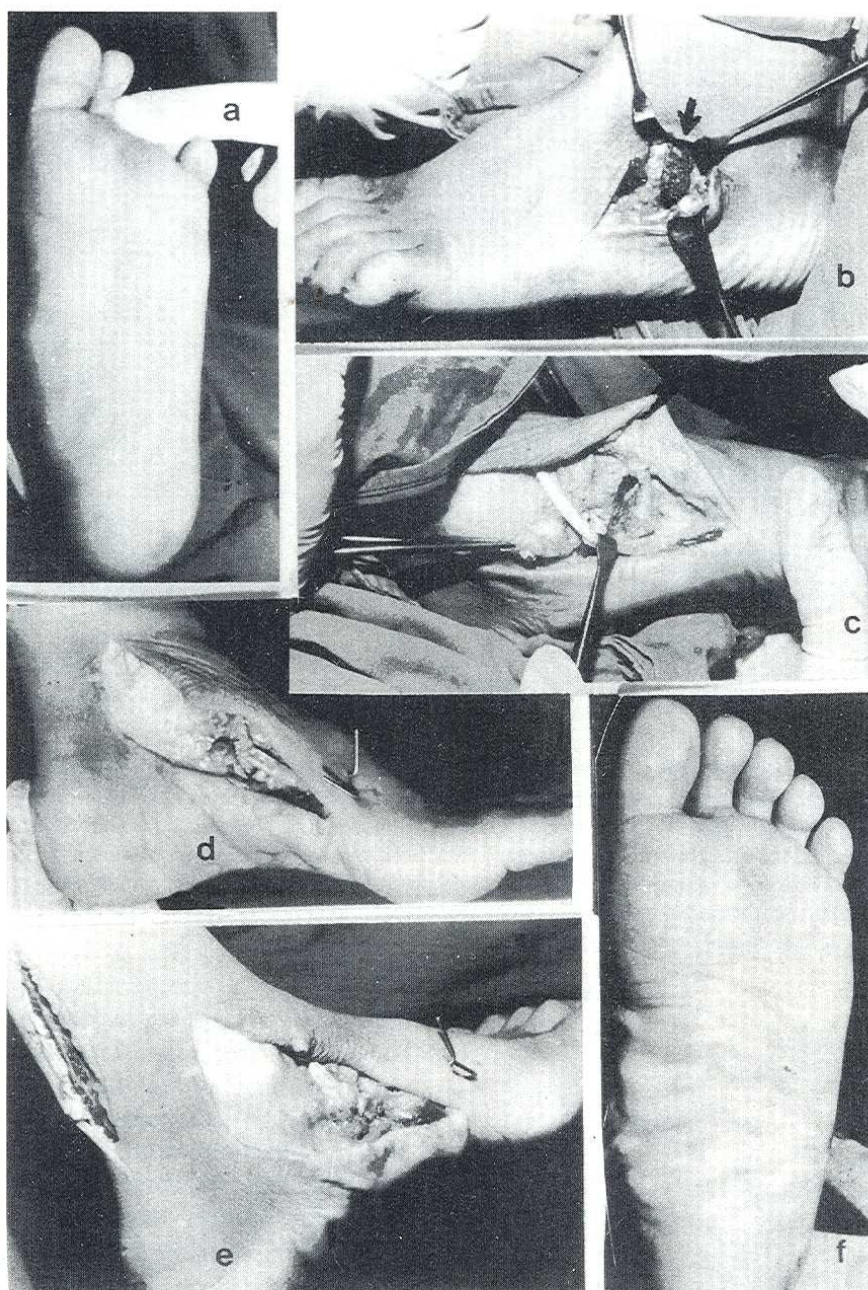


FIGURE 5 The operation in steps. *a*, The preoperative collapsed medial arch. *b*, The calcaneal distraction osteotomy is performed and the iliac graft is inserted and snugly fit. *c*, The naviculo-first cuneiform wedge resection is performed, after reflecting the osteoperiosteal flap proximally. Leaving its insertion undisturbed, the tibialis anterior tendon is pulled distally to traverse the naviculo-first cuneiform fusion and the talonavicular articulation. *d*, The tibialis anterior tendon is maintained in a plantar groove in the navicular tuberosity, sutured to the surrounding soft tissues and covered by the plicated osteoperiosteal flap. There is evident equinus of the ankle after reconstruction of the medial arch. *e*, Elongation of the tendo Achillis is essential. *f*, The arch is regained on table.

then sutured to the soft tissues plantar to the talar head. Then it is covered with the osteoperiosteal flap which is pulled distally to be plicated to the plantar soft tissues overlying the tibialis anterior tendon (Fig. 5d). The plantar segment of the tibialis anterior tendon with the tightened ligamentous flap will act as a strong plantar ligament supporting the naviculo-cuneiform fusion and the talonavicular articulation. The tibialis anterior tendon will act as a sling at its new insertion to the talar head (Fig. 5e). A

nonweightbearing below-knee plaster cast is applied for 8 weeks. This will allow healing of the ligamentous reconstruction, incorporation of the iliac graft, and fusion of the naviculo-cuneiform bones.

Clinical Outcomes

The results were assessed according to the improvement in the shape of the foot (cosmetic appearance),

shoewear, pain relief, and improvement in activity. Also the author considered an objective evaluation based on the improvement of the radiological values compared to the preoperative ones.

Results

Table 1 shows the results in the 19 feet with the corresponding subjective and objective results. Clinically the cosmetic appearance improved dramatically according to the comments of the patients and parents, except for one mother who was unhappy with the multiple residual scars from this procedure. The shape of the foot was considered satisfactory if there was a relative improvement or disappearance of heel valgus and forefoot abduction with reformation of the medial longitudinal arch (18 feet = 10 patients) (Fig. 6). Pain on prolonged standing and limitation of activity improved, yet it took the patients a few weeks to attain a normal gait.

Shoewear was of interest for both the parents and the surgeon and was practical proof of the improvement of the foot angles. Definite improvement in normal shoewear was clear in 12 out of 14 feet (eight patients). Slight but acceptable valgus of the heel was still present in two feet. One foot was considered unsatisfactory due to excessive elongation of the tendo Achillis, resulting in a mild calcaneus tendency of the foot with weak take-off

during walking and limited activity. This patient had the operation performed in both feet. The difference during walking was evident, and activity was limited in the affected foot. Another unsatisfactory result occurred in a foot that was relieved of pain, yet it did not improve in shape, and the medial longitudinal arch was still collapsed. The final end result was satisfactory in 17 feet (nine patients) and was unsatisfactory in two feet (two patients, one of whom had a bilateral procedure with a satisfactory result in the contralateral foot).

Radiographically, the naviculo-cuneiform fusion was evident in all except two cases, and the iliac graft was fully incorporated in the calcaneal osteotomy site 8–12 weeks postoperatively (Fig. 7). The different angle measurements were as follows: The lateral T1MT angle was corrected from an average of 30.1° (range, 13°–48°) to 8.5° (range, –5° to 25°) postoperatively. The T-H angle was corrected from an average of 40° (range, 22°–55°) to 21.5° (range, 12°–32°). The CP was corrected from an average of 4° (range, –5° to 12°) to 21.3° (range, 5°–35°), and the anteroposterior T1MT angle was corrected from an average of –16° (range, –25° to 0°) to an average of 2° (range, 0°–12°) (Fig. 8). Table 2 shows the averages, standard deviations, and Student's *t*-test values of the different radiographic measurements. The average improvement of all the angles was statistically significant at the 5% level [T1MT (*t*:12.25), T-H (*t*:12.86), CP (*t*:8.47), AP T1MT (*t*:10.30)].

TABLE 1 Data of the patients

Case Number	Age	Side	Prev. Op.	Sympt.	Radiological Measurements ^a				Criteria of Assessment				Result
					LAT. T1MT	LAT. T-H	LAT. CP	AP. T1MT	Pain Relief	Shoewear	Cosmetic	Activity	
1	9	R		PSCI	30/10	45/20	5/10	15/0	-	-	-	-	Satisfactory
		L			32/5	40/20	8/25	10/0	-	-	-	-	Satisfactory
2	10	L	STR	SC	35/10	35/15	3/30	0/0	-	-	-	-	Satisfactory
3	9	R	Evans	PSC	13/0	38/20	5/22	-10/0	-	-	-	-	Satisfactory
4	12	R		PSCI	20/0	30/12	0/18	-12/0	-	-	-	-	Unsatisfactory
5	10	L	Evans	PSCI	15/-5	22/18	12/30	-24/12	-	-	-	-	Satisfactory
		R			45/20	50/30	5/10	20/0	-	-	-	-	Satisfactory
6	13	R		PSC	48/10	40/32	5/10	25/2	-	-	-	-	Satisfactory
		L			35/25	55/30	0/5	-18/4	-	-	-	-	Satisfactory
7	12	L		PC	30/4	52/30	2/28	-15/2	-	-	-	-	Satisfactory
8	14	R		PCI	40/25	35/25	5/5	-8/10	-	-	-	-	Unsatisfactory
		L			38/8	48/20	5/15	-20/2	-	-	-	-	Satisfactory
9	9	R		PSC	35/10	50/25	8/30	-20/0	-	-	-	-	Satisfactory
		L			30/9	45/20	8/35	22/0	-	-	-	-	Satisfactory
10	11	R		PCI	22/12	40/20	3/27	20/5	-	-	-	-	Satisfactory
		L			25/5	30/15	3/24	-18/2	-	-	-	-	Satisfactory
11	9	R		PSC	25/12	32/18	10/30	-18/0	-	-	-	-	Satisfactory
		L			26/0	35/18	3/25	-15/0	-	-	-	-	Satisfactory
		R			28/10	38/20	2/20	13/0	-	-	-	-	Satisfactory
Average values					30.1/8.5	40/21.5	4/21.3	-16/2					

^aValues are given as preoperative/postoperative.

P, foot pains on long standing; S, shoewear; C, unsightly foot; I, inactivity; -, improved; ., no improvement.

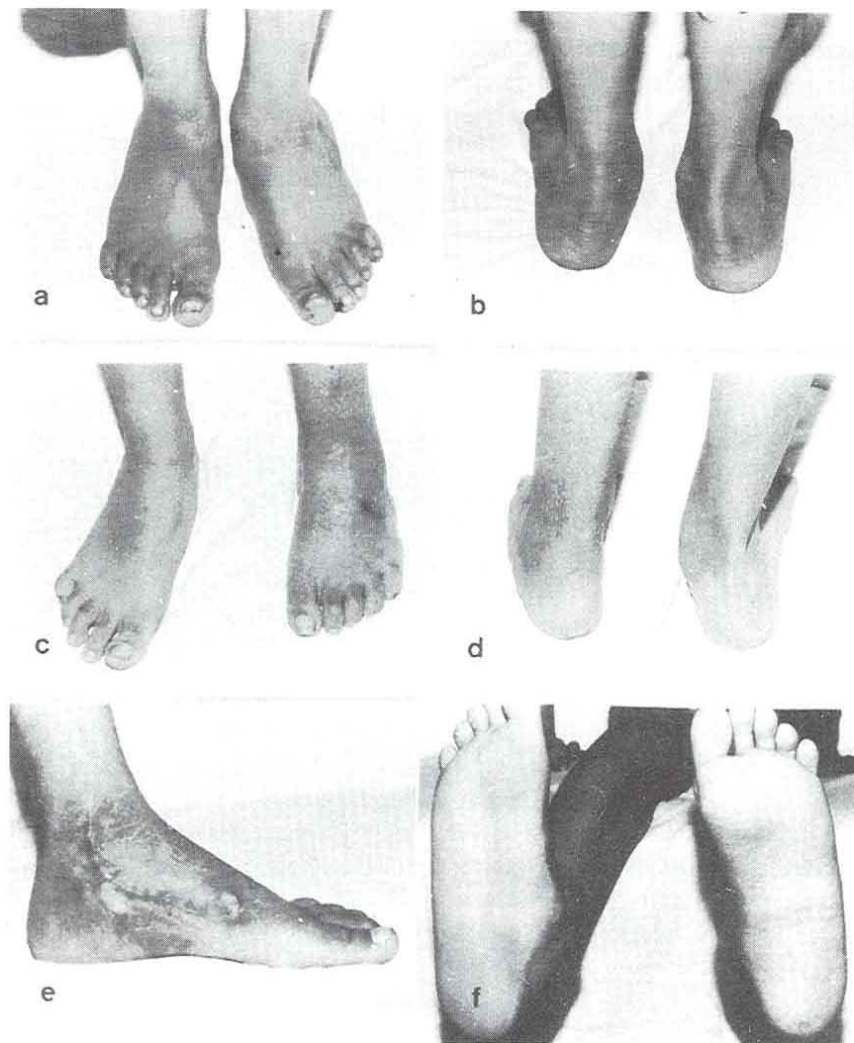


FIGURE 6 *a* and *b*, Preoperative front and back views of the left foot showing a collapsed medial arch and a valgus heel. *c* through *f*, Postoperative front, back, side, and plantar views showing a normal shaped foot with a reconstructed medial arch and a neutral heel. A satisfactory result at 6-month follow-up.

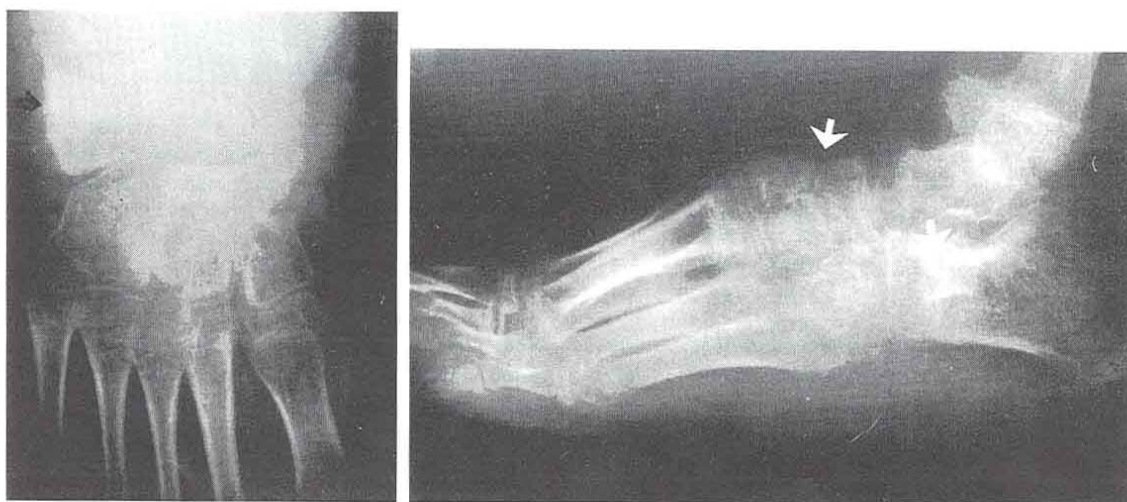


FIGURE 7 Radiological appearance at 12 weeks: full incorporation of the iliac graft at the calcaneal osteotomy and fusion of the naviculo-cuneiform bones medially.

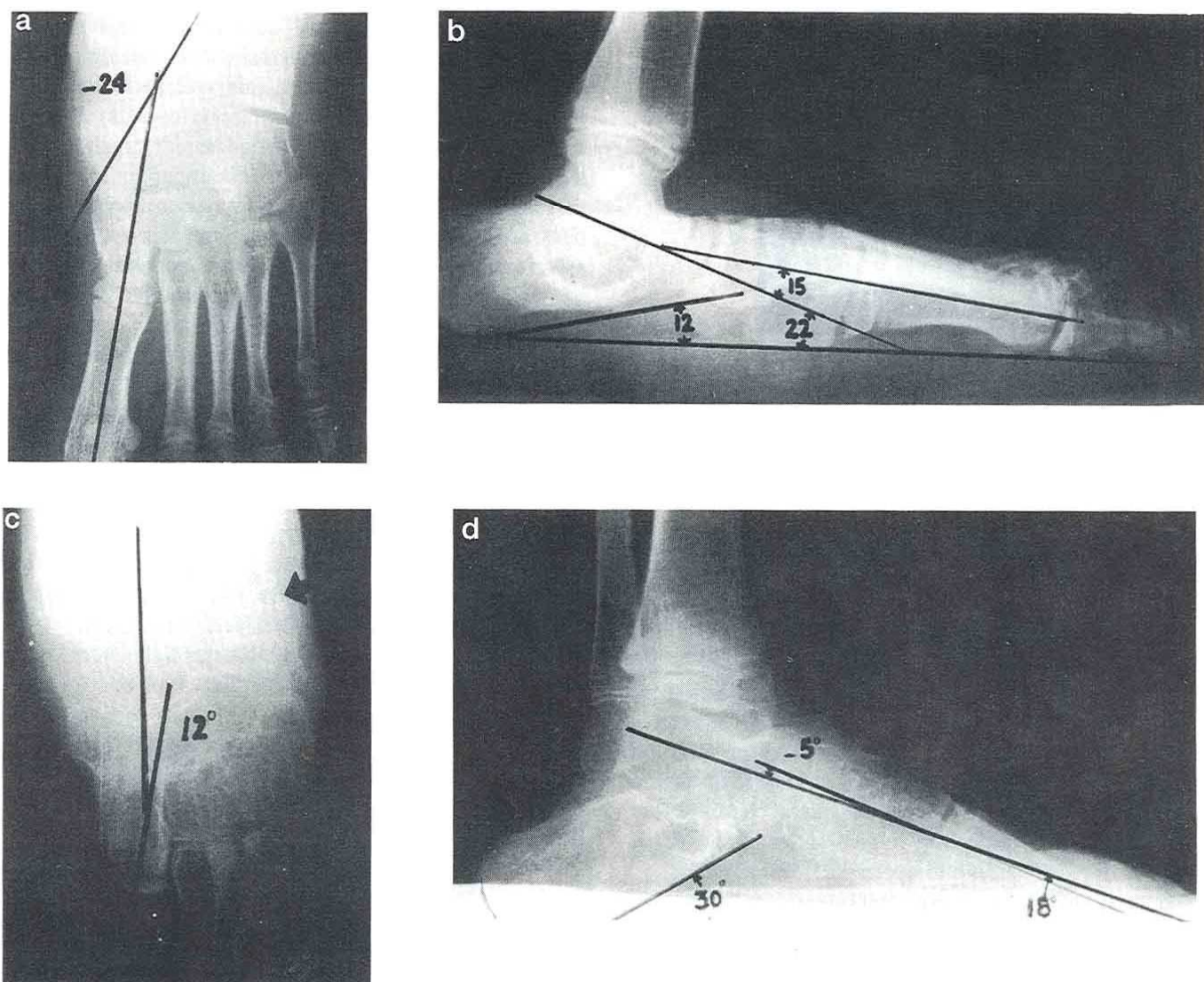


FIGURE 8 Improvement in radiological measurements. *a* and *b*, Preoperative standing radiographs with evidence of a resorbed iliac graft at site of an old Evans calcaneal osteotomy (case 4, left foot). The arch is flattened with naviculo-cuneiform sag and plantarflexed talus. *c* and *d*, Postoperative standing radiographs at 8 months with evident reconstruction of the arch, fusion of the naviculo-cuneiform articulation, and improvement in angle measurement.

TABLE 2 Averages, standard deviations, and student's *t* values for radiological measurement

	T1MT			T-H			CP			APT1MT		
	Pre	Post	Diff	Pre	Post	Diff	Pre	Post	Diff	Pre	Post	Diff
X	30.11	8.53	21.58	40.0	21.47	18.53	4.0	21.0	17	-15.95	205	-18.00
SD	9.25	8.47	7.68	8.68	5.67	6.28	4.26	9.33	8.75	6.13	3.50	7.62
<i>t</i>			12.25			12.86			8.47			10.30

Complications

Asymptomatic naviculo-cuneiform pseudarthrosis was seen on two occasions (Fig. 9). Apart from this, mild superficial pin-track infection was frequently seen and controlled by repeated dressing changes following removal of plaster and K-wires.

Discussion

The human foot arch may become apparent during a 7- or 9-year period (7, 8). Operative correction may be performed for severe symptomatic flexible flatfoot in patients as young as 4, 9, or 10 years (4, 5, 9, 10). Evans recommended that his procedure be performed on

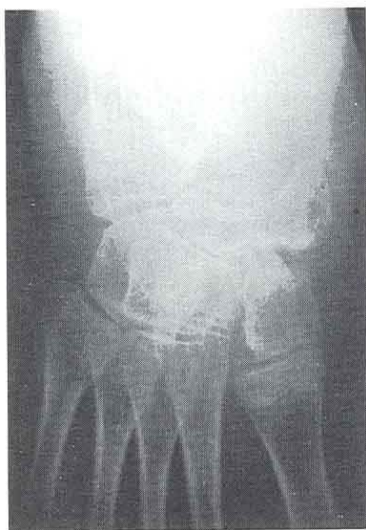


FIGURE 9 Naviculo-cuneiform pseudarthrosis at 6-month follow-up.

patients between ages 8 and 12 years (11). In this study the surgery was reserved for children 9–14 years old with symptomatic severe flatfeet. The main indication for surgery was failure of the usual conservative measures to relieve symptoms, namely pain related to the foot and calf, generalized inactivity (3, 5), and excessive distortion and wear of shoes (1, 7). Cosmetic appearance of the foot bothered the parents especially in girls and was considered as part of the evaluation and operative considerations.

The long-term results of different procedures for correction of the symptomatic severe flexible flatfoot were disappointing because most surgeons failed to recognize the multiplicity of factors contributing to the deformity. The dynamically loaded arch is maintained by osseous and ligamentous support and to a lesser extent by muscle contraction (12). The Evans procedure was either used alone (11, 13, 14) or in combination with either soft-tissue (1, 5) or bony procedures (15). Others have transferred the tibialis anterior insertion to the talar neck without addressing the bony component of the deformity (16). The described combined procedure aimed at reconstruction of all factors at fault in one sitting.

For the collapsed medial column with eversion of the heel, the Evans calcaneal osteotomy was performed. It is a lengthening, distraction-wedge osteotomy advancing the calcaneocuboid portion of the midtarsal joint that makes the calcaneocuboid joint axis more convergent with the talonavicular joint (10). At the time of surgery, the medial arch was restored even before attempting naviculo-cuneiform wedge resection and fusion. Lengthening the lateral column alone and ignoring the other components of the deformity may end with failure and was seen in a patient with bilaterally operated feet that needed revision.

The aim of the naviculo-cuneiform wedge resection (medial and plantar) was to shorten the medial column and restore the medial arch. This will facilitate plantar ligamentous reconstruction and will allow easy rerouting and suture of the tibialis anterior tendon to the plantar aspect of the reconstructed arch. It is important to point out that arthrodesis of the naviculo-cuneiform joint is never performed independent of other procedures and is used as an adjunctive procedure for total surgical correction of the foot (3). When performed alone, the medial arch fusion may yield poor results (14). In fact, this procedure is superior to open wedge cuneiform osteotomy which adds to the length of the medial column, rendering plantar reconstruction and rerouting of the tibialis anterior tendon extremely difficult or even impossible. It is believed that the medial column shortening by naviculo-cuneiform wedge resection will relieve compressive forces applied laterally over the calcaneal graft during the reparative stage (17), which is an accepted explanation for the resorption of the graft and loss of correction in the case that required revision after the Evans procedure.

Significant elongation of the plantar ligamentous complex was addressed by developing a plantar osteoperiosteal flap based proximally. This was then advanced distally to be plicated to the surrounding soft tissues. This was augmented by the distal end of the tibialis anterior, which was rerouted to traverse the plantar aspect of the fused naviculo-cuneiform joint.

Realizing that the talus is responsible for the entire function of the foot, and that in the pronated flatfoot the talus becomes anteriorly displaced with adduction and plantarflexion, Kissel and Blackledge (16) utilized the transfer of tibialis anterior through the talus from dorsal lateral to plantar medial for direct talar control. The remaining tendon end was sutured to the plantar soft tissues as a "ligament." In this study, this idea was modified. The tibialis anterior tendon was not disturbed and its distal 10–15 cm were mobilized to allow easy redirection of the distal end to attain a L course, the horizontal limb of which formed a strong plantar ligament, while the vertical limb was shortened and sutured to the talar head to augment the upward pull on the medial arch. Since it is primarily a swing-phase muscle, the tibialis anterior can continue to act as an ankle joint dorsiflexor after its transfer to the talus (16).

Contracture of the Achilles tendon often accompanies the symptomatic flatfoot (11, 18). It prevents normal dorsiflexion of the ankle during the midstance phase of the gait cycle. The dorsiflexion stress is shifted to the talonavicular joint, subjecting the underlying soft tissues to excessive direct axial loading and shear forces. Z plasty of the tight tendo Achillis is always needed to bring the ankle to at least 10°–15° of dorsiflexion (5, 16, 19). Lengthening of the tendo Achillis was performed in all feet in this

study before proceeding with naviculo-cuneiform fusion and plantar ligamentous reconstruction. The tendo Achilles was excessively lengthened in one foot, resulting in weak heel take-off during walking.

In this study, a trapezoid-shaped iliac graft was utilized to maintain lengthening of the lateral column at the calcaneal osteotomy as recommended by Mosca (5). This allowed total calcaneal advancement, which is believed to be superior to the V-shaped graft (15, 20), which allowed lateral forward advancement only. The trapezoid graft was also easy to shape and apply. Fenestration and K-wire fixation of the graft to ensure stability enhanced union at the osteotomy site. The smaller the graft, the shorter the time span of repair (17). In this study, the thickness of the graft at the lateral border of the calcaneus did not exceed 1.5 cm in all cases. Typically, the graft is 1.0–1.2 cm long laterally, as recommended by Mosca (5). Overcorrection is highly unlikely, and the metatarsus adduction angle will increase only 1.5° with a 4.6-mm graft (7). In this study, only a few degrees of metatarsus adduction were seen at follow-up, due to overlengthening of the lateral column which was intended at the time of surgery to overcome the possibility of mild graft resorption at the calcaneal osteotomy.

The total casting period ranged from 6 to 8 weeks to allow healing of soft-tissue reconstruction. Eight weeks were estimated for incorporation of the iliac graft (5), while others recommended a 5- to 8-week period (16). In this study, the graft was fully incorporated at 8–12 weeks postoperatively. Slipping of the iliac graft reported by some authors (5) was not seen in this series, since K-wire fixation was used in all cases. Also, subluxation of the distal calcaneal fragment was avoided by respecting the ligaments of the calcaneocuboid articulation.

Radiologically, the naviculo-cuneiform fusion was evident in all except two feet. These were most probably due to inadequate cartilage resection. Congruency of the talonavicular articulation and alignment of the medial column were greatly improved. Relative improvement in the radiological measurements in the anteroposterior and lateral weightbearing views was statistically significant and was considered clinically significant once it fell within the normal ranges mentioned by Mosca (5). The radiographic improvement was related to the clinical reshaping of the foot. The final result was considered satisfactory in 17 feet (89.5%).

The proposed combined procedure proved effective in addressing all components of the deformity. The lateral column was lengthened, the medial column was additionally shortened, the elongated plantar ligaments were plicated and augmented by the horizontally directed distal

end of the tibialis anterior tendon, and, lastly, the tibialis anterior muscular pull was augmented through its relative shortening by shifting its insertion proximally to act as an arch sling to the talar head, thus maintaining the reconstructed medial arch. A useful correction of a significant deformity in relatively young children will prevent more serious deformity later in life. Thus the incidence of degenerative joint disease and need for arthrodesing procedures in adulthood can be eliminated.

References

1. Cohen-Sobel, F., Giorgini, R., Velez, Z. Combined technique for surgical correction of pediatric severe flexible flat foot. *J. Foot Ankle Surg.* 34(2):183–194, 1995.
2. Clark, G. C. A modified Kinder procedure for symptomatic flat foot. *Clin. Orthop.* 228(3):258–260, 1988.
3. Dockery, G. L. Symptomatic juvenile flat foot condition: Surgical treatment. *J. Foot Ankle Surg.* 34(2):135–145, 1995.
4. Fraser, R. K., Menelaus, M. B., Williams, P. F., Cole, W. G. The Miller procedure for mobile flat foot. *J. Bone Joint Surg.* 77-B(3):396–399, 1995.
5. Mosca, V. S. Calcaneal lengthening for valgus deformity of the hindfoot. *J. Bone Joint Surg.* 77-A(4):500–512, 1995.
6. Viladot, A. Surgical treatment of the child's flat foot. *Clin. Orthop.* 283(10):34–38, 1992.
7. Barry, R. J., Scranton, P. E. Flat feet in children. *Clin. Orthop.* 181(10):68–75, 1983.
8. Vanderwilde, R., Staheli, L. T., Chew, D. A. Measurements on radiographs of the foot in normal infants and children. *J. Bone Joint Surg.* 70-A:407–415, 1988.
9. Duncan, J. W., Lovell, W. W. Modified Hoke-Miller flat foot procedure. *Clin. Orthop.* 181(12):24–27, 1983.
10. Brim, S. P., Hecker, R. The Evans calcaneal osteotomy: Postoperative care and an evaluation of the metatarsus adductus angle. *J. Foot Ankle Surg.* 33(1):2–5, 1994.
11. Evans, D. Calcaneo valgus deformity. *J. Bone Joint Surg.* 57-B:270–278, 1975.
12. Basmajian, J., Steco, G. The role of muscles in arch support of the foot. *J. Bone Joint Surg.* 45-A(6):1184–1189, 1963.
13. Phillips, G. E. A review of elongation of os calcis for flat foot. *J. Bone Joint Surg.* 65-B:15–18, 1983.
14. Seymour, N. The late results of naviculo-cuneiform fusion. *J. Bone Joint Surg.* 49-B:558–559, 1967.
15. Dollard, M. D., Marcinko, D. E., Lazerson, A., Elleby, D. H. The Evans calcaneal osteotomy for correction of flexible flat foot syndrome. *J. Foot Surg.* 23(4):291–301, 1984.
16. Kissel, C. G., Blackledge, D. K. Tibialis anterior transfer into talus for control of the severe planus pediatric foot: a preliminary report. *J. Foot Ankle Surg.* 34(2):195–199, 1995.
17. Burchardt, H. The biology of bone repair. *Clin. Orthop.* 174:28–42, 1983.
18. Harris, R. L., Beath, T. Hypermobile flat foot with short tendo Achilles. *J. Bone Joint Surg.* 30-A(1):116–138, 1948.
19. Schwartz, N. H., Tursi, F. J. A new surgical technique for the treatment of pes planus deformity: a preliminary report. *J. Foot Surg.* 26(2):149–152, 1987.
20. Alter, S. A., Licovski, L. Bone grafting for reconstructive osteotomies of the foot. *J. Foot Ankle Surg.* 35:418–427, 1996.